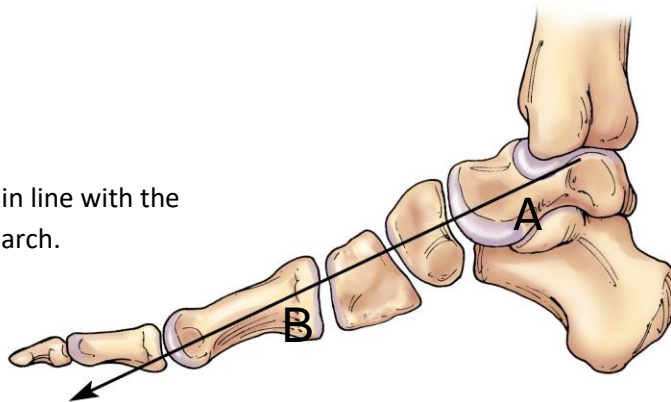


# Calcaneal Lengthening for Flatfoot Deformity

A normal arch is present when the x-ray demonstrates a normal bony alignment. A line drawn through the ankle bone will pass through the head of the great toe bone (first metatarsus) in a normal arch. This alignment on the x-ray is more important than how the foot appears when weight bearing (Figure 1)

Figure 1: The ankle bone (A) is in line with the great toe bone (B) in a normal arch.



The presence of normal flexibility of the foot and the absence of a contracture of the heel cord allow the foot to grow normally for most children

However, conditions such as cerebral palsy, contracture of the heel cord, tarsal coalition, hyperlaxity, hypermobility, or juvenile idiopathic arthritis may alter the growth and development of the arch. A stiff and painful flatfoot results in abnormal shoe wear. It will cause most children to walk and run more slowly. It may result in large calluses on the instep of the arch and if a brace is normally worn it may be painful.

Orthotics may temporarily decrease pain in an abnormal arch, but it has never been shown that the arch returns to normal despite the length of wear.

If the pediatric orthopedic surgeon determines that the loss of the arch is significant but reversible, then a surgical option will be presented (Figure 2).

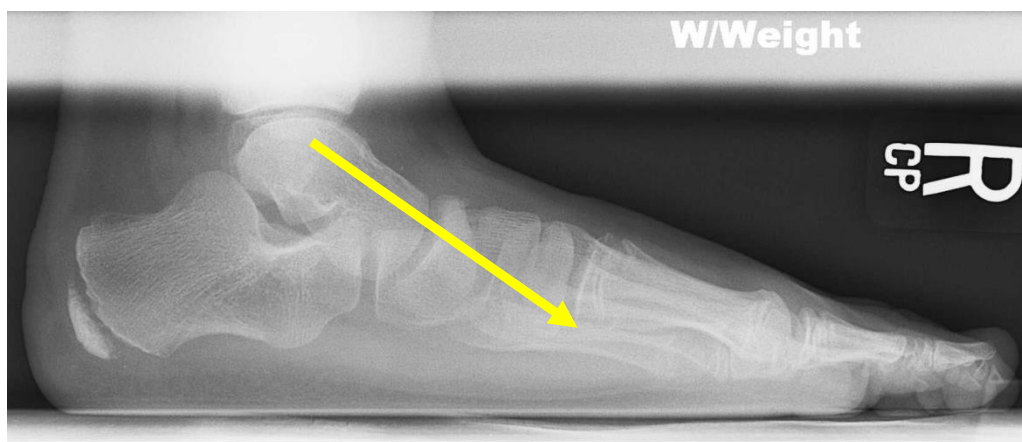


Figure 2: The yellow line passing through the ankle bone does not line up with the great toe bone. This means that the arch is abnormal.

If there are contractures of the tendons around the foot, these will be lengthened. Then the outside of the calcaneus is cut in half, and a wedge of bone is inserted and secured with a pin or bone staple. The wedge of bone will aid in restoring a normal alignment of the ankle bone with the great toe bone (figures 3A and 3B).

Figure 3 A

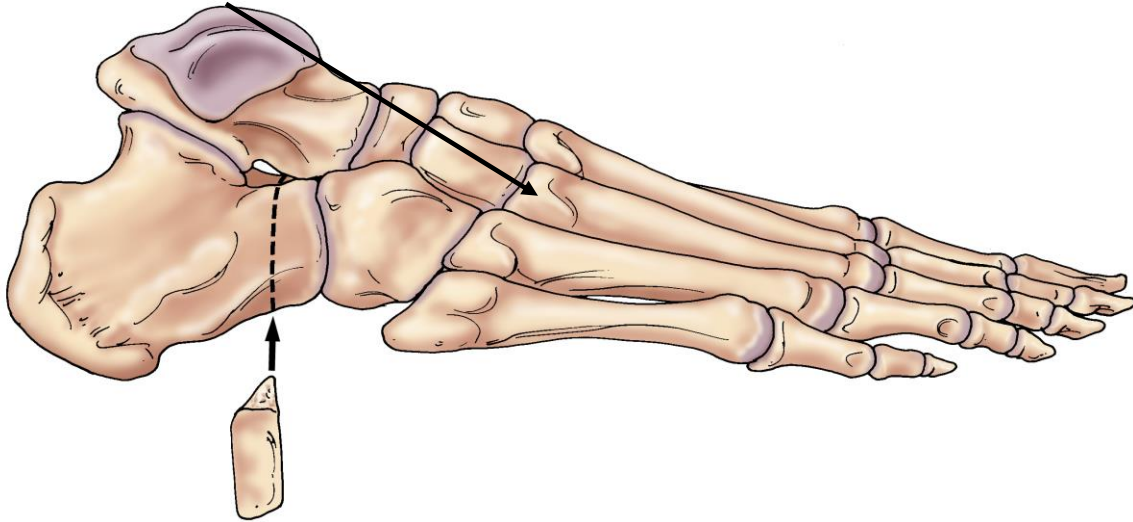
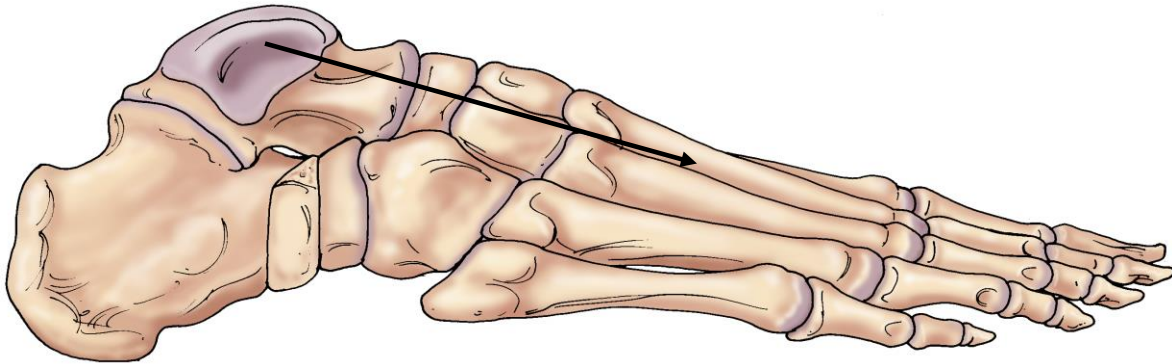


Figure 3 B



After surgery, a non-weight bearing cast will be used for 4-6 weeks while the graft and lengthened tendons are healing. A walking cast or rigid brace will follow next. The underlying condition that contributed to the loss of the arch may dictate that a brace or shoe insert is then used.

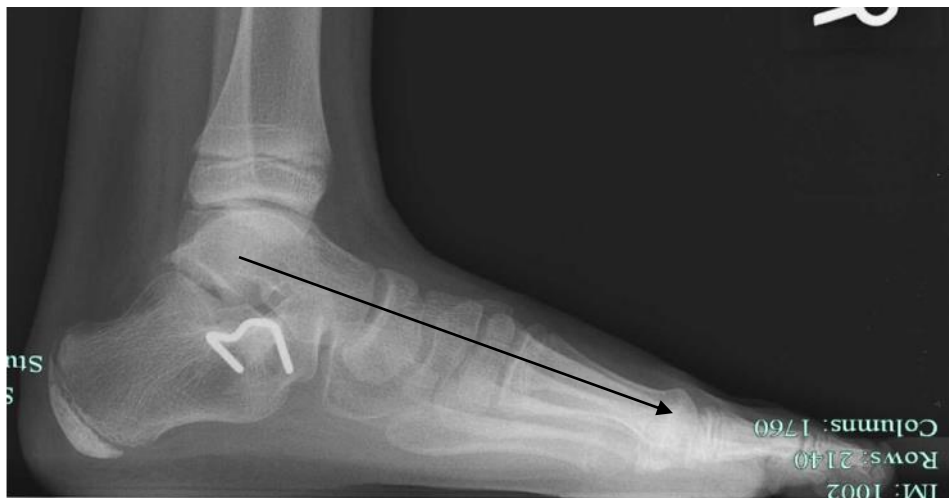

Figure 4: The insertion of a bone graft into the heel bone has realigned the ankle bone so that it now points directly to the great toe bone.

